



*This is an enhanced PDF from The Journal of Bone and Joint Surgery*

*The PDF of the article you requested follows this cover page.*

---

## **Effects of Acquired Glenoid Bone Defects on Surgical Technique and Clinical Outcomes in Reverse Shoulder Arthroplasty**

Steven M. Klein, Page Dunning, Philip Mulieri, Derek Pupello, Katheryne Downes and Mark A. Frankle  
*J Bone Joint Surg Am.* 2010;92:1144-1154. doi:10.2106/JBJS.I.00778

---

**This information is current as of November 20, 2010**

### **Supporting data**

<http://www.ejbjs.org/cgi/content/full/92/5/1144/DC1>

### **Reprints and Permissions**

Click here to [order reprints or request permission](#) to use material from this article, or locate the article citation on [jbjs.org](http://jbjs.org) and click on the [Reprints and Permissions] link.

### **Publisher Information**

The Journal of Bone and Joint Surgery  
20 Pickering Street, Needham, MA 02492-3157  
[www.jbjs.org](http://www.jbjs.org)

# Effects of Acquired Glenoid Bone Defects on Surgical Technique and Clinical Outcomes in Reverse Shoulder Arthroplasty

By Steven M. Klein, MD, Page Dunning, BA, Philip Mulieri, MD, PhD, Derek Pupello, MBA, Katheryne Downes, MPH, and Mark A. Frankle, MD

*Investigation performed at the Foundation for Orthopaedic Research and Education, Tampa, Florida*

**Background:** Reverse total shoulder arthroplasty is the accepted method of treatment for selected shoulder disorders. The purpose of this study was to compare primary reverse shoulder arthroplasty surgical techniques as well as clinical and radiographic outcomes in patients with acquired glenoid bone defects and in those with normal glenoid morphology.

**Methods:** Preoperative three-dimensional computed tomography scans were performed on 216 shoulders in 211 patients undergoing primary reverse shoulder arthroplasty between 2004 and 2007. The glenoids were classified as normal or abnormal on the basis of preoperative radiographs and three-dimensional reconstructions of the scapula. One hundred and forty-three shoulders had been followed for two years. There were eighty-seven normal and fifty-six abnormal glenoids. The surgical techniques that were compared included bone-grafting and glenosphere selection. The clinical outcomes for the two groups were compared with respect to the American Shoulder and Elbow Surgeons score.

**Results:** Surgical technique differed between the groups. All fifty-six glenoids with acquired bone defects had center screw placement along an alternative (scapular spine) centerline. A bone graft was used in twenty-two shoulders with acquired glenoid bone defects compared with none of those with normal glenoid morphology ( $p = 0.016$ ). Shoulders with glenoid defects were treated with larger glenospheres (36 or 40 mm) more often than those with normal glenoids ( $p < 0.001$ ). No significant difference was detected between the groups with regard to the preoperative or postoperative American Shoulder and Elbow Surgeons scores. Radiographs did not demonstrate failure or resorption of a glenoid bone graft when present. All outcomes improved significantly postoperatively. There were five complications, and one patient was unsatisfied with the result.

**Conclusions:** Glenoid bone defects, when managed with an alteration of surgical technique, including bone-grafting when indicated, are not a contraindication to reverse total shoulder arthroplasty.

**Level of Evidence:** Therapeutic Level IV. See Instructions to Authors for a complete description of levels of evidence.

Reverse total shoulder arthroplasty has become an accepted method of treatment for a range of shoulder disorders associated with rotator cuff dysfunction. A wide range of pathologic osseous changes can result from the altered kinematics caused by a torn rotator cuff. Often, the drastic departure from normal anatomy can present challenges to conventional strategies in reverse shoulder arthroplasty. Previous reports on primary reverse shoulder arthroplasty for massive, irreparable rotator cuff tears have shown promising short-term results<sup>1,2</sup>. Reverse shoulder arthroplasty in the

revision setting has not typically achieved a similar level of success<sup>3-6</sup>. This may be due to several factors, including glenoid bone loss. The challenges in the revision setting can also occur in primary reverse shoulder arthroplasty. Frankle et al. reported that up to 37.5% of patients receiving a primary reverse shoulder arthroplasty acquired glenoid bone defects because of altered kinematics<sup>7</sup>.

A variation in glenoid morphology and its effect on total shoulder arthroplasty for osteoarthritis have been reported. Several techniques to accommodate bone loss, including

**Disclosure:** In support of their research for or preparation of this work, one or more of the authors received, in any one year, outside funding or grants in excess of \$10,000 from DJO Surgical. In addition, one or more of the authors or a member of his or her immediate family received, in any one year, payments or other benefits in excess of \$10,000 or a commitment or agreement to provide such benefits from a commercial entity (DJO Surgical).

preferential reaming, the use of specialized glenoid components<sup>8</sup>, and structural bone-grafting<sup>9</sup>, have been described. Despite these efforts, substantial glenoid bone loss in the setting of either primary or revision total shoulder arthroplasty has been associated with inferior outcomes<sup>8-12</sup>. To date, there is little information in the literature addressing how substantial alterations in glenoid morphology associated with a massive, irreparable rotator cuff tear affect treatment strategies and clinical outcomes in the setting of primary reverse shoulder arthroplasty. Classification schemes have been developed to describe the progressive radiographic changes in cuff tear arthropathy<sup>13-15</sup>. The Seebauer classification also attempted to establish a treatment algorithm for cuff tear arthropathy on the basis of the severity of radiographic changes and the stability of the joint<sup>13</sup>. None of the existing classifications, however, link the deformity caused by cuff tear arthropathy to the treatment and expected outcomes. Acquired glenoid bone defects may necessitate alterations in surgical technique to make implantation of the baseplate possible and to avoid inferior outcomes<sup>16-18</sup>.

The primary purpose of this study was to compare outcomes after a primary reverse shoulder arthroplasty in patients with and without glenoid bone loss as previously classified by Frankle et al.<sup>7</sup>. Our hypothesis was that patients with acquired glenoid bone defects undergoing reverse shoulder arthroplasty would have inferior outcomes compared with patients with normal glenoid anatomy. Our secondary purpose was to analyze the surgical technique used in patients with either normal or abnormal glenoid bone stock.

## Materials and Methods

### Patient Selection

In a previous investigation<sup>7</sup>, radiographs and computed tomography scans were used to classify the glenoid morphology in 211 patients (216 shoulders) treated with a primary reverse shoulder arthroplasty from October 2004 through December 2007. Patients included in the study presented for a primary reverse shoulder arthroplasty after failing to respond to nonoperative measures. Our current investigation is an institutional review board-approved study to examine the clinical outcomes of the patients in the previous study. A cohort of 141 patients (143 shoulders) with minimum of two years of follow-up (average, 30.9 months; range, twenty-four to fifty-one months) was included in the current series (Table I). The average age of the patients at the time of surgery was  $71.7 \pm 8.3$  years (range, forty-two to eighty-seven years). Of the 143 shoulders, fifty (35%) were in men and ninety-three (65%) were in women. Surgery was performed on eighty-five right shoulders (59%) and fifty-eight left shoulders (41%). Reverse shoulder arthroplasty was performed for an underlying diagnosis of primary rotator cuff deficiency (massive, irreparable rotator cuff tear and no previous surgery) in seventy-eight shoulders (55%), failed rotator cuff surgery in sixty-three shoulders (44%), and fracture sequelae in two shoulders (1%). All surgical procedures were performed by the senior author (M.A.F.).

TABLE I Patient Demographics and Surgical Information

Demographics	
Patients	
Total no. (shoulders/patients)	143/141
No. of shoulders in women	93
No. of shoulders in men	50
Average age (range) (yr)	72 (42-87)
Average follow-up interval (range) (mo)	31 (24-51)
Surgical information (no. of shoulders)	
Reason for arthroplasty	
Primary rotator cuff deficiency	78
Failed rotator cuff repair	63
Fracture sequela	2
Glenoid morphology	
Normal glenoid	87
Abnormal glenoid	56
Side affected	
Right	85
Left	58

### Anatomic Evaluation

Details of the anatomic measurements for the group have been described previously<sup>7</sup>. Briefly, each patient underwent a preoperative radiographic evaluation (anteroposterior; anteroposterior tangential to the face of the glenoid with the arm in neutral rotation, i.e., a true anteroposterior or Grashey view of the glenohumeral joint; axillary; and outlet or scapular Y views) and two-dimensional computed tomography scans (with a slice thickness of  $\leq 1$  mm). The computed tomography scans were further used to create three-dimensional reconstruction models: the original computed tomography scan images, after isolating the scapula from the other structures, were converted into a stereolithography file by the program Mimics (Materialise, Leuven, Belgium) and then were imported into a computer-aided design program (SolidWorks, Concord, Massachusetts). Glenoid morphology was classified as either normal (eighty-seven shoulders; 61%) or abnormal (fifty-six shoulders; 39%) by three independent observers on the basis of (1) plain radiographs alone, (2) a combination of plain radiographs and two-dimensional computed tomography scans, and (3) the three-dimensional computed tomography reconstruction models (Fig. 1). Abnormal glenoids (those with acquired osseous defects) were then further subdivided by the site of erosion into posterior (twenty-five shoulders; 17%), superior (sixteen; 11%), global (eleven; 8%), and anterior (four; 3%). Anatomic measurements of the scapulae (see Appendix) were made with use of three-dimensional reconstruction images of each and included the glenoid height, width, version, and inclination; the distance from the coracoid base

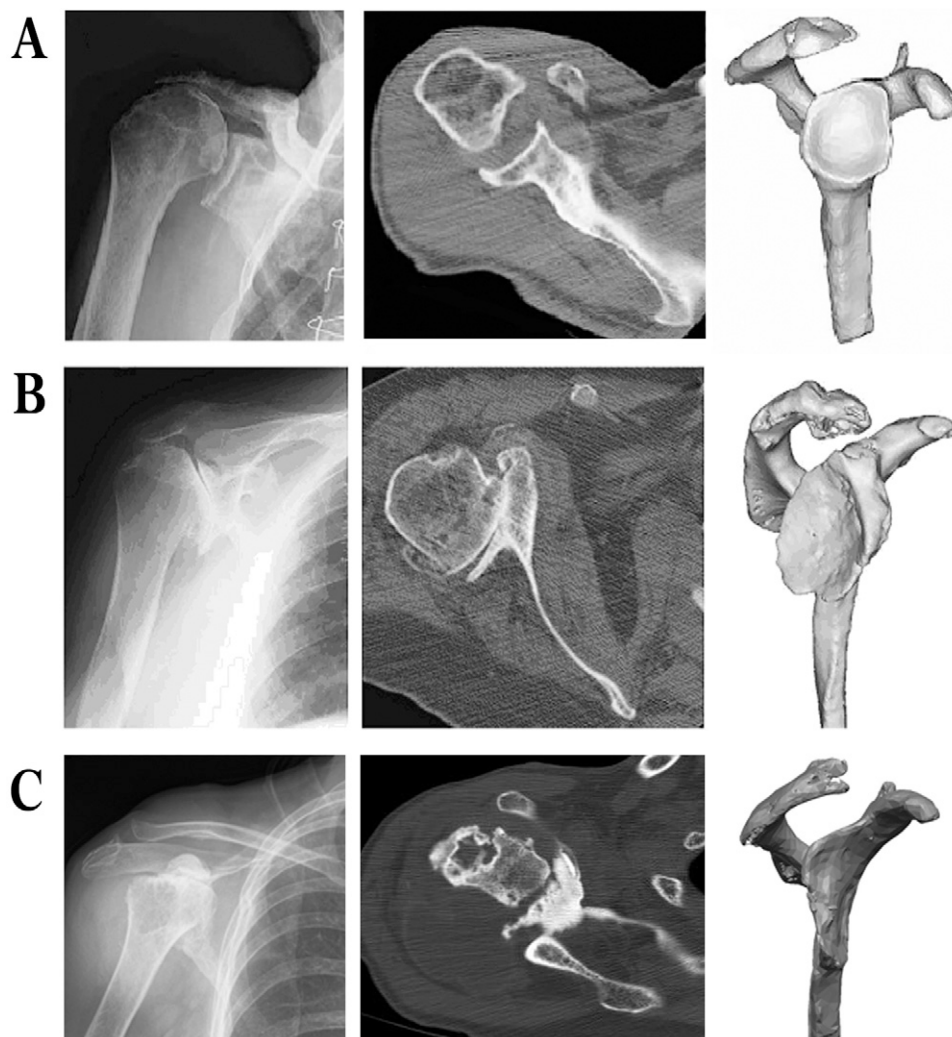


Fig. 1  
Plain radiograph, axial two-dimensional computed tomography scan, and three-dimensional computed tomography reconstruction model of a shoulder with normal glenoid morphology in a seventy-two-year-old man (A), in a shoulder with abnormal glenoid morphology and posterior bone loss in a seventy-four-year-old man (B), and in a shoulder with abnormal glenoid morphology and anterior bone loss in an eighty-five-year-old woman (C).

to the glenoid surface; and the distance from the acromion base to the glenoid surface (Fig. 2). Additionally, the bone available for purchase by the baseplate was determined by measuring the standard centerline perpendicular to the glenoid surface (defined as the line that originated in the center of the glenoid, perpendicular to the articular surface, and exited on the anterior aspect of the scapular neck)<sup>19,20</sup> and the alternative scapular spine centerline (defined as the point that originated in the center of the glenoid and then was aligned with the scapular spine but was not necessarily perpendicular to the glenoid surface). The glenoid area available for peripheral screw placement was measured in the quadrants and columns with use of a previously described technique<sup>7</sup>.

### *Surgical Technique*

Insertion of the reverse shoulder arthroplasty glenoid baseplate (Reverse Shoulder Prosthesis; DJO Surgical, Austin, Texas) in the eighty-seven shoulders with normal glenoid morphology proceeded in a standard fashion<sup>2,21</sup>. In these shoulders, the ideal position of the central screw followed the path of the standard glenoid centerline (Fig. 3, A) as described by Matsen et al.<sup>19</sup> and Bicos et al.<sup>20</sup>. This placement results in the baseplate being oriented perpendicular to the glenoid surface and the central screw exiting anteriorly on the scapular body.

The surgical technique was modified in the fifty-six shoulders with acquired glenoid bone defects (as determined by preoperative radiographic evaluation and intraoperative inspection). In all fifty-six shoulders with acquired glenoid

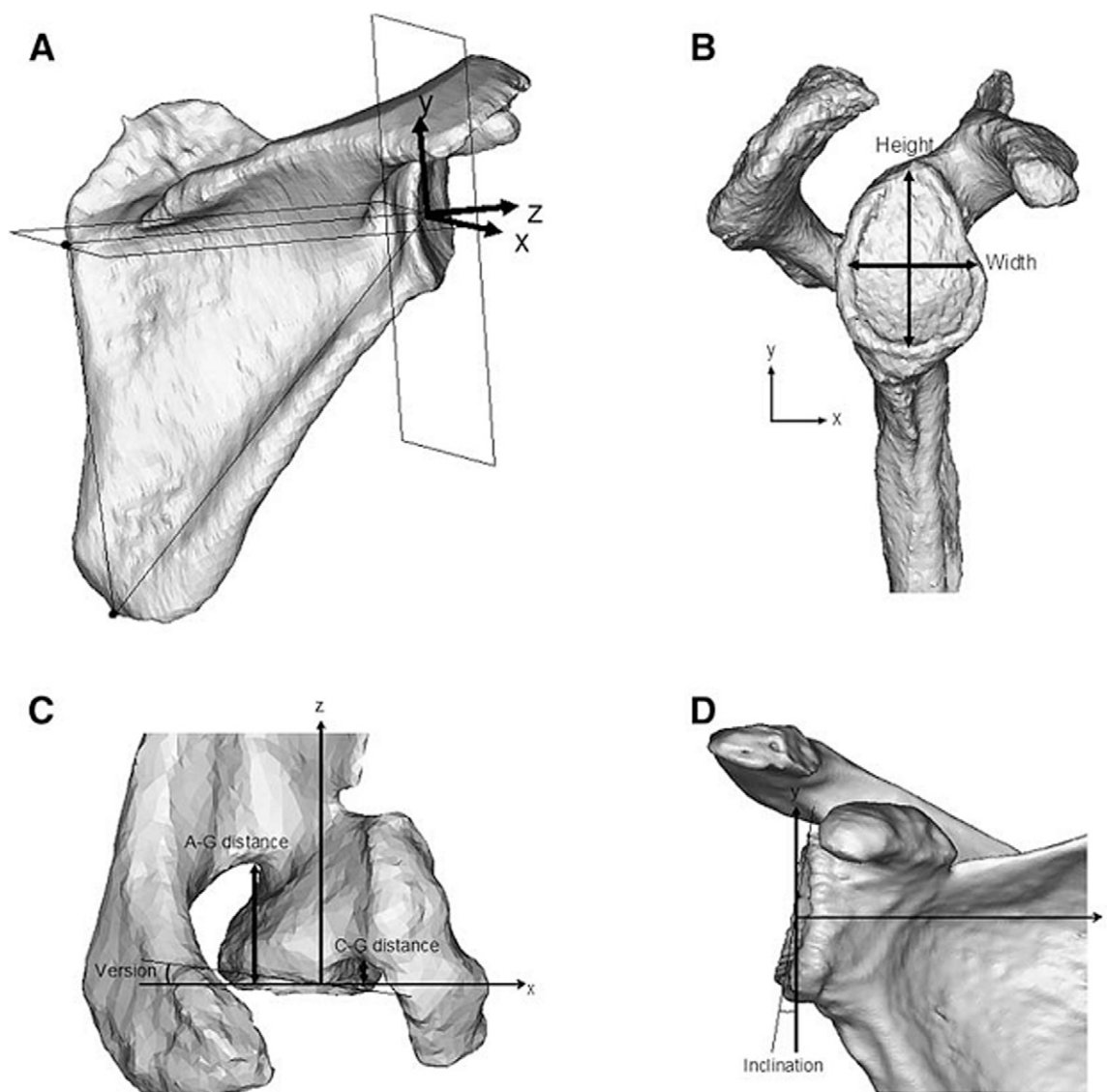


Fig. 2

The anatomic measurements used in glenoid morphology are the scapular coordinate system (A); the glenoid height and width (B); the glenoid version, the distance from the coracion base to the glenoid surface (C-G distance), and the distance from the acromion base to the glenoid surface (A-G distance) (C); and the glenoid inclination (D). (Reprinted from: Frankle MA, Teramoto A, Luo ZP, Levy JC, Pupello D. Glenoid morphology in reverse shoulder arthroplasty: classification and surgical implications. *J Shoulder Elbow Surg.* 2009;18:874-85; with permission from Elsevier.)

bone defects in the current series, a different orientation of the central screw was used to increase the amount of bone captured. This alternative centerline originated from the center of the glenoid surface, passed along the axis of the scapular spine, and passed through the junction of the scapular spine as it joined the body of the scapula<sup>7</sup> (Fig. 3, B and C).

After the central hole was drilled along the spine centerline, depth gauge measurement confirmed a minimum screw length of 25 mm. The tap was then placed, and a cannulated glenoid reamer prepared the glenoid surface. If <80% of the underside of the glenoid baseplate was in contact with the reamed glenoid (Fig. 4) because of eccentric bone loss,

which occurred in twenty-two of the fifty-six shoulders, either a bulk graft from the humeral head (twenty-one shoulders) or a femoral head allograft (one shoulder) was used. The graft was contoured and placed directly into the defect and was held in place by either Kirschner wires or a 3.5-mm screw. The construct was then reamed to conformity with the tap still in place. The tap was then removed and the baseplate inserted. The baseplate was tightened to provide compression of the graft to the native glenoid surface (Fig. 5). Five-millimeter locking screws were placed, and the temporary Kirschner wires were removed. The structural graft was then sculpted around the implant with a burr.

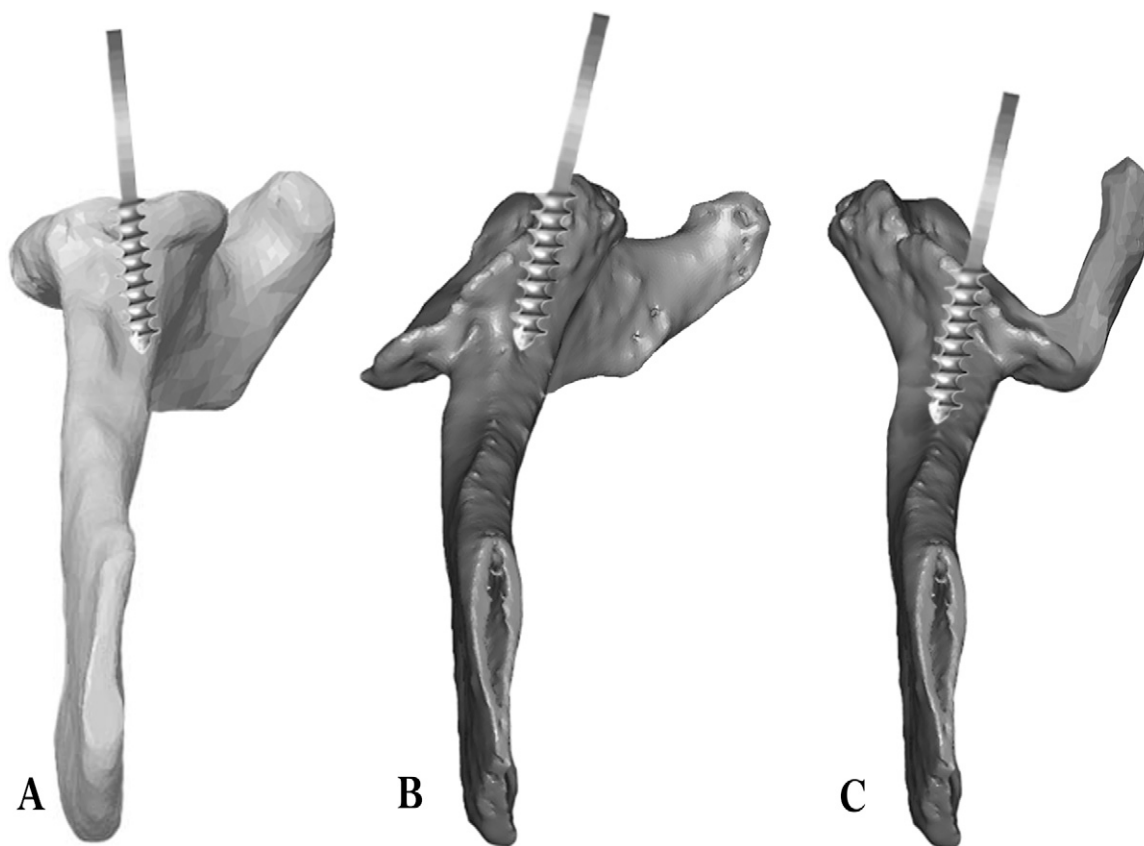


Fig. 3

Inferior axial view of the scapula with the acromion removed for clarity. A: Scapula with normal glenoid morphology. The baseplate tap is inserted down the standard centerline. B: Scapula with posterior bone erosion. The tap is anteverted slightly for insertion down the spine centerline. C: Scapula with anterior bone erosion. The tap is also anteverted slightly for insertion down the spine centerline.

Glenosphere selection was based, first, on the presence of a glenoid defect and, second, on the ability of the components to provide stability without restricting motion. In the presence of a defect, a larger glenosphere was selected for 46% (twenty-six) of fifty-six shoulders to adequately cover the defect. In glenoids without bone loss, a smaller size (32-mm [-4-mm offset], which has a 6-mm center of rotation lateral to the glenoid surface, for female patients and 32-mm [neutral offset], which has a 10-mm center of rotation lateral to the glenoid surface, for male patients<sup>21</sup>) was routinely used. The humeral socket chosen for 89% (127) of the 143 shoulders was the standard (neutral) size. Next, the shoulder was reduced, and humeral and glenoid component articulation was verified. Finally, shoulder range of motion was tested. If the shoulder was unstable or there was a restriction in motion due to tight soft-tissue structures, both components would be changed to achieve the optimal combination.

A larger glenosphere with a hood was utilized in fifteen shoulders to overhang and protect the graft (Figs. 6 and 7). All operations were performed in a single stage regardless of glenoid morphology. All humeral components were cemented in 30° of retroversion. The system utilized in this

study contains humeral sockets with different thicknesses: the neutral thickness for each diameter is the thinnest, and the +4-mm and +8-mm sockets represent an increase in the thickness of the polyethylene relative to the neutral socket of 4 or 8 mm, respectively. In the eighty-seven shoulders with normal glenoid morphology, a neutral socket was selected for 92% (eighty shoulders); a +4-mm socket, for 7% (six shoulders); and a +8-mm socket, in one shoulder. In the fifty-six shoulders with acquired glenoid bone defects, a neutral socket was placed in 84% (forty-seven shoulders); a +4-mm socket, in 13% (seven shoulders); and a +8-mm socket, in 3% (two shoulders). Socket height was chosen on the basis of soft-tissue tension during trial insertion of the components.

#### *Clinical Evaluation*

Patients were followed clinically for a minimum of two years. At each follow-up visit, data were routinely collected for the American Shoulder and Elbow Surgeons (ASES) scores<sup>22</sup>, the Simple Shoulder Test (SST)<sup>23</sup>, and a 10-point visual analog scale for pain and function. All range-of-motion measurements reported were active range of motion and were made

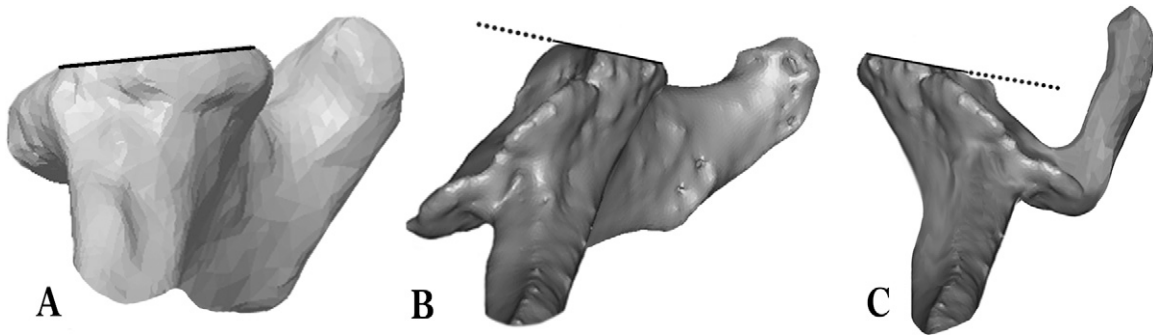


Fig. 4

A: The glenoid surface following standard reaming of a normal glenoid for insertion of the baseplate. B: The glenoid surface following reaming with slight anteversion because of posterior bone loss for which the anterior portion of the glenoid surface is preferentially reamed. C: The glenoid surface following reaming with slight anteversion because of anterior bone loss for which the posterior portion of the glenoid surface is preferentially reamed. At this point, if <80% of the baseplate (dashed line) is in contact with the glenoid bone, bone graft is used.

preoperatively and postoperatively with use of a previously described method<sup>24</sup>.

### Radiographic Evaluation

Postoperative radiographs were reviewed for all 143 shoulders. The initial radiographs were compared with interval radiographs through the patient's most current follow-up. The standard four radiographs of the shoulder, including an anteroposterior radiograph, an anteroposterior tangential radiograph with the arm at neutral rotation (a true anteroposterior or Grashey radiograph of the glenohumeral joint), an axillary radiograph, and an outlet or scapular Y-view radiograph, were compared to identify any evidence of component failure or notching, progressive radiolucent lines, or obvious baseplate or graft failure. The Grashey radiographs were evaluated at each postoperative visit, and they were compared with successive radiographs to determine what, if any, interval changes occurred. Finally, the first postoperative radiographs were compared with the most recent radiographs, and any radiolucencies at that time were noted.

### Statistical Analysis

#### Outcomes Assessment

A post hoc power analysis was performed on the basis of our primary outcome measure, the ASES score. This analysis revealed that a minimum sample size of thirty-seven was required to detect a 15-point difference in the ASES score<sup>25</sup> ( $\alpha = 0.05$  and  $\beta = 0.90$ ). Preoperative and postoperative outcome measures as well as range of motion were compared for all patients and between groups on the basis of sex, glenoid morphology, use of bone graft, and glenosphere size. The normality of all variables was evaluated with use of the Kolmogorov-Smirnov test. Comparisons between the patients with normal morphology and those with acquired glenoid bone defects with regard to the scores obtained preoperatively and postoperatively were conducted with use of the non-parametric Mann-Whitney U test to determine whether there were baseline differences between the two groups. The differ-

ences between preoperative and postoperative values were then analyzed with use of a t test with a Levene test to evaluate equality of variance. All variables including outcome scores, glenosphere size, and the use of bone graft were compared on the basis of patient sex and glenoid morphology with use of either the t test or the Mann-Whitney U test for continuous variables and either the Fisher exact test or the chi-square test for categorical variables. Alpha was set at 0.05.

### Morphologic Analysis

Previously collected data<sup>7</sup> on the morphologic features of the glenoid, including height, width, inclination, version, acromial-glenoid distance, coracoid-glenoid distance, standard centerline distance, and spine centerline distance, as well as the peripheral screw placement area, were used for the current study. These values were compared, with use of the t test or Mann-Whitney U test, on the basis of glenoid morphology (normal or acquired glenoid bone defects) and the need for bone graft.

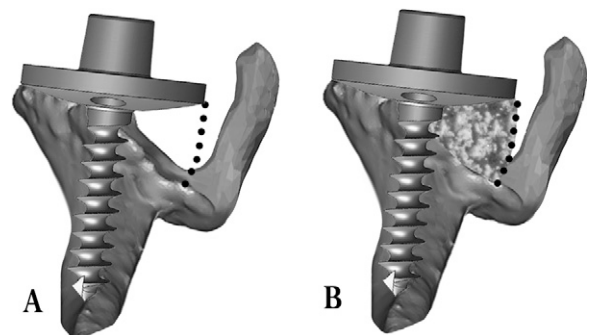


Fig. 5

A: Baseplate insertion down the spine centerline for anterior bone loss. Because of bone erosion, <80% of the underside of the baseplate would be in contact with the glenoid bone. B: A bone graft is placed in the defect before insertion of the baseplate.



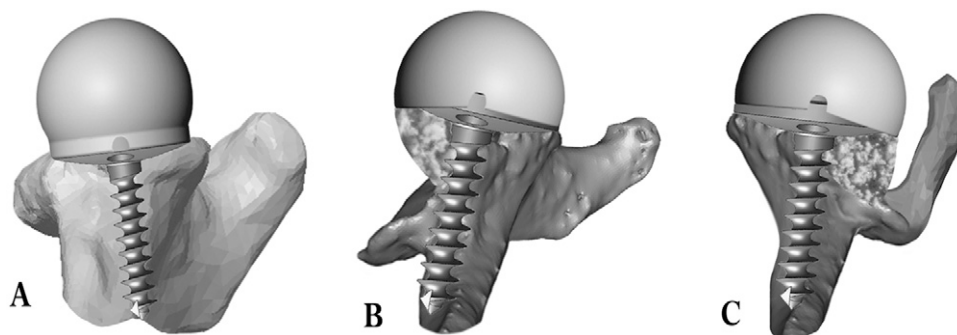


Fig. 6

A: A standard glenosphere is used with a normal glenoid. B: A glenosphere with an extended hood is oriented to cover the bone graft for posterior bone loss. C: A glenosphere with an extended hood is oriented to cover the bone graft for anterior bone loss.

### Surgical Technique Analysis

Operative technique was analyzed retrospectively to identify accommodations made for various types of glenoid erosion. Particular attention was given to the use of bone graft and the size of glenosphere selected. These factors were first compared between the normal and acquired glenoid osseous defect groups in a univariate analysis. Next, a multivariate regression analysis with use of forward stepwise likelihood ratio methods was performed to determine the independent effects of variables, including patient sex, glenoid morphology, patient age at the time of surgery, and previous rotator cuff surgery, on operative technique (selection of glenosphere size and use of bone graft).

### Source of Funding

The Foundation for Orthopaedic Research and Education, a private foundation, received research support from DonJoy Orthopaedic Surgical (DJO Surgical). DJO Surgical manufactures the Reverse Shoulder Prosthesis under investigation. The senior author (M.A.F.) is the designing surgeon for the Reverse Shoulder Prosthesis.

### Results

#### Outcomes Assessment

##### All Patients

A summary of the preoperative and postoperative ASES and SST scores and the range of motion for all patients is presented in the Appendix. All mean outcomes for the entire group improved postoperatively ( $p < 0.0001$ ). The mean total ASES score improved from 39.1 to 75.1, the mean SST score improved from 1.9 to 6.4, and the mean visual analog pain score improved from 6.1 to 1.5. Range-of-motion analysis revealed improvements in the mean values for forward flexion (from  $67^\circ$  to  $140^\circ$ ), abduction (from  $65^\circ$  to  $126^\circ$ ), external rotation (from  $19.8^\circ$  to  $49^\circ$ ), and internal rotation (from a spinal level of S1 to L2). The outcome was rated as excellent by eighty patients, good by forty-one, satisfactory by nineteen, and unsatisfactory by one.

##### Patient Subsets

Preoperative and postoperative range of motion and functional scores (including ASES, SST, and visual analog scale scores) were also compared for specific patient subsets (Table II and Appendix). There were significant differences between male

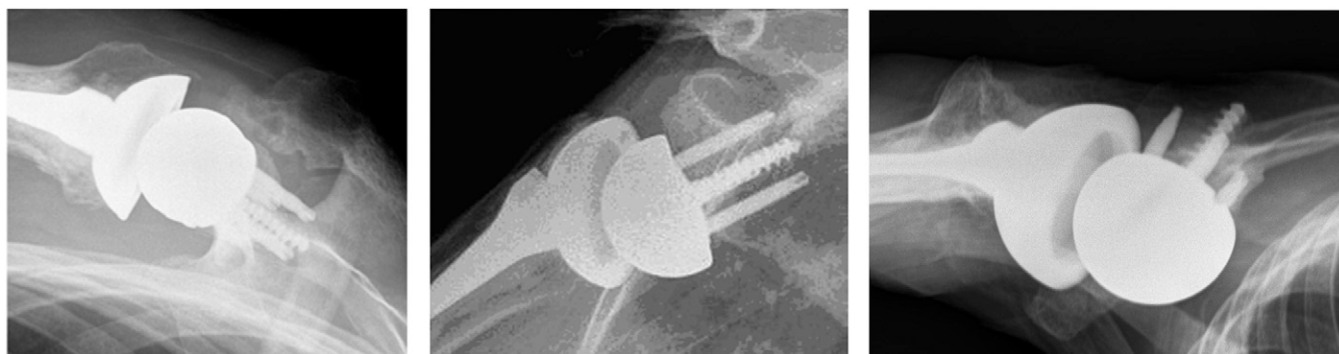

Fig. 7

Left: Postoperative radiograph of the seventy-two-year-old man in Figure 1, A, showing normal version of the glenoid component. Middle: Radiograph of the seventy-four-year-old man in Figure 1, B, showing the glenoid baseplate slightly anteverted and the glenosphere oriented so that the hood covers the posterior bone graft. Right: Radiograph of the eighty-five-year-old woman in Figure 1, C, showing the glenoid baseplate slightly anteverted and the glenosphere oriented so that the hood covers the anterior bone graft.



and female patients on the preoperative SST scores ( $p = 0.002$ ) and differences that were approaching significance on the postoperative ASES function and SST scores; however, these findings disappeared when preoperative and postoperative differences were compared. No significant difference was detected when the patients were grouped by glenoid morphology or use of bone graft.

#### Postoperative Radiographs

No evidence of failure was noted with respect to the graft or component loosening in any shoulder. No radiolucent line was noted at the baseplate-bone interface. No progressive radiolucent lines were evident around the bone-cement interface on the humeral component. One shoulder with grade-2 notching of the scapular neck, according to the Nérot grading system<sup>26</sup>, was noted in a patient with normal glenoid morphology. This finding was seen on the one-year postoperative radiograph. No progression was noted through the thirty-six-month follow-up period, and thus the patient continued to be treated conservatively.

#### Morphology

##### Normal Compared with Abnormal Glenoid Morphology

Significant differences between these groups were seen with respect to the glenoid height, width, inclination, coracoid-to-glenoid distance, acromion-to-glenoid distance, centerline distance, spine centerline distance, and peripheral screw area (Table II).

#### Bone Graft

Glenoids with acquired osseous defects that were treated with bone-grafting were compared with abnormal glenoids that had

not had grafting. Glenoids treated with bone-grafting had a greater amount of erosion preoperatively as depicted by an increase in inclination (mean, 19.9° compared with 13.5°;  $p = 0.0065$ ) (Table II).

#### Surgical Technique

##### Bone Graft

Bone-grafting was performed in twenty-two of 143 shoulders. Twenty-two (39%) of the fifty-six abnormal glenoids received a bone graft, and no normal glenoid was treated with a graft ( $p = 0.016$ ).

##### Glenosphere Size

The most commonly used glenosphere sizes in all patients were a 32-mm (−4-mm offset) glenosphere (59%), a 32-mm (neutral offset) glenosphere (17%), and a 36-mm (−4-mm offset) glenosphere (15%). The other sizes (thirteen shoulders) were excluded from the remaining analyses because of low sample sizes. Univariate analysis revealed that glenosphere size varied depending on three factors: glenoid morphology ( $p < 0.001$ ), sex ( $p < 0.001$ ), and bone-graft use ( $p = 0.016$ ). Among the shoulders with normal morphology, the majority had implantation of either a 32-mm (−4-mm offset) glenosphere (77%) or a 32-mm (neutral offset) glenosphere (21%). Shoulders with acquired glenoid bone defects demonstrated a different distribution, with a 32-mm (−4-mm offset) glenosphere implanted in 47% and a 36-mm (−4-mm offset) glenosphere implanted in 39%, indicating a shift toward larger sized implants. In the presence of bone graft, a 32-mm (−4-mm offset) implant was used in 27% (six) of twenty-two shoulders and a 36-mm (−4-mm offset) glenosphere was used

TABLE II Anatomic Measurements of Normal and Abnormal Glenoids

	Normal Glenoids (N = 87)	Abnormal Glenoids (N = 56)		Comparison of Glenoids with and without Grafting ( <i>p</i> value)	Comparison of Normal and Abnormal Glenoids ( <i>p</i> value)
		Treated with Bone-Grafting (N = 22)	No Bone-Grafting (N = 34)		
Height* (mm)	34.9 (27.4-43.9)	38.5 (29.7-53.7)	38.2 (26-50.9)	0.594	<0.0001†
Width* (mm)	29 (22.5-35.6)	31.2 (21.6-51.7)	33 (22.5-55)	0.2167	<0.0001†
Version* (deg)	−7.6 (−22.4-0)	−3.9 (−43.5-37.9)	−10.8 (−41.5-24.1)	0.0966	0.7232
Inclination* (deg)	13 (−6.5-23.7)	19.9 (1.2-42.1)	13.5 (−12.4-27.3)	0.0065†	0.0203†
Distance from coracoid to glenoid* (mm)	3.1 (−2.4-8.5)	−2.2 (−12.3-6.4)	−0.5 (−14.1-8.3)	0.2614	<0.0001†
Distance from acromion to glenoid* (mm)	21 (15.6-26.6)	16.1 (5.9-22.09)	19.6 (9.3-27.1)	0.1704	<0.0001†
Standard centerline* (mm)	28.5 (20.7-39.5)	20.6 (11.5-38.1)	22.9 (10.9-33.7)	0.2151	<0.0001†
Alternative centerline* (mm)	42.6 (21-104.7)	27.4 (11.7-69.6)	32.5 (17.6-87.3)	0.0702	0.0031†
Median screw surface area (mm <sup>2</sup> )	774.7	429.8	472.9	0.5959	0.0186†

\*The values are given as the mean, with the range in parentheses. †Significant ( $p < 0.05$ ).

in 55% (twelve shoulders). Sex was also found to have significant effects on the size of glenosphere chosen. The most frequently used sizes in women were 32-mm (–4-mm offset) (80%) and 36-mm (–4-mm offset) (19%), but the most commonly used sizes in men were 32-mm (neutral offset) (55%) and 32-mm (–4-mm offset) (36%). Logistic regression accounting for glenoid morphology, bone-grafting, sex, prior rotator cuff surgery, and age at the time of surgery revealed that the four factors identified in univariate analysis remained significant predictors for different device sizes. Specifically, female sex ( $p < 0.001$ ) and no use of bone graft ( $p = 0.021$ ) were predictive for 32-mm (–4-mm offset) glenosphere placement, and male sex ( $p < 0.001$ ) was predictive of 32-mm (neutral offset). Normal morphology was associated with placement of both 32-mm (–4-mm offset) and 32-mm (neutral offset) glenospheres, whereas the use of bone graft was strongly predictive of placement of a 36-mm (–4-mm offset) glenosphere.

### Complications

There were five complications. Two shoulders had an acromial fracture, which was treated nonoperatively. Two shoulders had a deep infection; one was treated with a two-stage revision and the other with extensive irrigation and débridement along with single-stage revision surgery. The remaining complication was a periprosthetic fracture that occurred when the patient lifted a heavy tree. The shoulder was treated nonoperatively. Of the patients with complications, two rated the outcome as excellent; two, as good; and one, as satisfactory. All complications, with the exception of the periprosthetic fracture, were in the group with normal morphology.

### Discussion

The present study showed that, in patients who have a primary reverse shoulder arthroplasty, surgical techniques can be modified to accommodate glenoid bone loss in shoulders with acquired osseous defects of the glenoid. Additionally, it showed, in contrast to our hypothesis, that patients with acquired glenoid bone defects can have clinical outcomes comparable with those in patients with normal glenoid morphology. These results indicate that, with a modified surgical technique, reverse shoulder arthroplasty for patients with acquired glenoid bone defects can yield short-term clinical outcomes similar to those in patients with normal glenoid morphology.

Our understanding of reverse shoulder arthroplasty has advanced substantially in recent years. This has enabled patients to obtain outcomes beyond the limited goals once set for shoulders with rotator cuff deficiency accompanied by varying degrees of arthritis<sup>27</sup>. However, glenoid bone loss continues to present a challenge in shoulder arthroplasty. Much of the literature regarding glenoid bone loss has been in the setting of conventional, unconstrained total shoulder arthroplasty, for which various strategies for glenoid component reimplantation have been described<sup>18,9,11,12,28–32</sup>. Overall, the results have been consistently inferior to outcomes in primary total

shoulder arthroplasty without glenoid bone loss, regardless of technique. Failure rates of up to ten times that of primary arthroplasty without glenoid bone loss have been reported<sup>9–12</sup>. The consequences of not accounting for glenoid bone loss during reverse shoulder arthroplasty implantation have been linked to compromised outcomes as well<sup>18,24,33</sup>. The majority of the literature on the topic of glenoid bone loss is in the setting of revision surgery. However, on analyzing our patients presenting for a primary reverse shoulder arthroplasty, we found that 37.5% of them had an abnormal glenoid because of bone loss<sup>7</sup>. Although the prevalence of patients with glenoid bone loss in the general population is largely unknown, our experience suggests that this problem may occur with greater frequency than has been previously recognized.

Regardless of the type of shoulder arthroplasty planned, inadequate bone stock to support a glenoid component has been discussed as a reason to abandon component placement altogether because of the likelihood of decreased functional outcomes and early failure<sup>2,12,34,35</sup>. However, techniques to accommodate for bone loss and allow glenoid component implantation during reverse shoulder arthroplasty have been reported<sup>5,16,17,32</sup>. Neyton et al.<sup>16</sup> reviewed the cases of nine patients with a Grammont-type reverse shoulder arthroplasty who underwent glenoid bone-grafting for severe bone loss. At a minimum two-year follow-up period, their results showed good pain relief but low postoperative functional scores (a mean Constant score of 53 points), and six patients had radiographic evidence of inferior scapular notching. Elhassan et al.<sup>17</sup> reported on twenty-one patients who had reconstruction of the glenoid with a femoral head allograft because of insufficient bone stock during revision shoulder arthroplasty. Three of the patients underwent a Grammont-type reverse shoulder arthroplasty. Those patients were noted to have improvements in the level of pain and forward flexion but an overall decrease in external rotation.

To our knowledge, the present study is the first to compare outcomes of reverse shoulder arthroplasty in patients with and without glenoid bone loss. Despite the challenges presented by bone loss, clinical results in all outcomes measured were not significantly or clinically different from those achieved by the group with normal glenoid morphology. This may be due to several factors inherent in the reverse shoulder arthroplasty design that increase the constraint of the shoulder relative to that of an anatomic total shoulder replacement and make stability and proper soft-tissue tension attainable. Greater surface contact area between the glenosphere and socket in conjunction with the reversal of the articulation neutralizes the destabilizing force of the deltoid. This neutralization enables the baseplate to be relatively anteverted<sup>7</sup> in order to accommodate for glenoid bone loss. Despite this anteversion, no shoulder had a dislocation.

Additionally, we believe that in the setting of acquired glenoid bone defects, initial fixation of the baseplate is of paramount importance in the surgeon's ability to successfully implant a glenoid component. By implanting the baseplate in the scapular body along the spine centerline, it is possible to

achieve stable fixation even when bone loss is present. No glenoid fixation failure was observed in either patient group during the follow-up period. This appears to indicate that the initial fixation of the central axis of the glenoid baseplate (in this case, a central screw) is critical and can allow for the addition of peripheral osseous support with a bone graft. In our current series, the selection of the alternative scapular spine centerline made it possible to achieve stable glenoid fixation in all shoulders with an abnormal glenoid regardless of the level and location of bone loss.

However, preoperative identification of the level and location of bone loss is an important part of surgical planning. Identification of glenoid bone defects on standard shoulder radiographs should prompt further imaging, including a computed tomography scan with three-dimensional reconstruction. These images can help to guide placement of the central screw (the central axis of the baseplate) into adequate bone for initial fixation. Both the standard glenoid centerline and spine centerline axis should be identified and the proper alignment selected for the baseplate to allow for maximal central screw fixation. Additionally, identification of segmental bone loss, which may prevent sufficient contact with the backside of the baseplate, can be anticipated preoperatively. We found that abnormal glenoids that were supplemented with bone graft had greater glenoid inclination (in the superior direction) than those that had not had grafting. Osseous contact with the backside of the baseplate can be improved with the addition of bulk autograft or allograft to fill eccentric voids in the glenoid.

In addition to initial fixation of the baseplate, proper soft-tissue tensioning may play an important role in improving functional outcomes following reverse shoulder arthroplasty. The selection of various glenosphere sizes in our series reflects alterations in the soft-tissue envelope secondary to either altered glenoid morphology and/or sex. All glenosphere selections were made on the basis of the surgeon's perception of soft-tissue tension to provide a stable shoulder with a range of motion that was unencumbered by the remaining soft-tissue structures. Male patients and patients with acquired glenoid bone defects were treated more frequently with larger glenospheres. Patients who received a larger glenosphere had substantial improvement in all planes of motion including forward flexion (mean, 65.5° to 141°), abduction (mean, 63° to 127.7°), external rotation (mean, 21.2° to 43.9°), and internal rotation (mean, S1 to T12). We suspect that the smaller glenospheres in female patients relate to their smaller stature and, therefore, were selected at the time of surgery to accommodate the diminished volume of the soft-tissue envelope. Currently, there is little information available to assess optimal soft-tissue tension, but we believe that correct soft-tissue tensioning contributes to a successful outcome after reverse shoulder arthroplasty.

One weakness of our study was the lack of a true control group. Patients who had a glenoid with normal morphology were compared with a series of patients with acquired glenoid bone defects that required treatment with a modified tech-


nique. There was no control group consisting of patients with glenoid bone defects implanted with a reverse shoulder replacement with use of the standard technique. Therefore, while the modifications in surgical technique assisted in our ability to implant the device, we cannot isolate the effect of surgical technique on clinical outcomes. It is difficult to say whether glenoid fixation would have been possible without modifying the surgical technique.

Additionally, it is important to note that while radiographic outcomes were encouraging, these were not fluoroscopic views and radiographic follow-up was short term. Grashey radiographs were evaluated at each postoperative visit, and they were compared with successive radiographs to determine what, if any, interval changes occurred. Finally, the first postoperative radiographs were compared with the most recent radiographs and any radiolucencies at that time were noted.

Another weakness of the study was that the results were based on a single surgeon using a single type of prosthesis at a unique tertiary-care center that has the longest experience with reverse shoulder arthroplasty in the United States. As such, our experience may not represent that of practices outside the realm of a subspecialty-based tertiary-care referral center or that of practitioners who either have less experience or use other reverse shoulder devices. Techniques utilized in the study were employed with an implant design containing a baseplate with a central compression screw and a center of rotation lateral to the glenoid. Alternative techniques may be necessary to accommodate the varying baseplate and glenosphere designs currently available. Finally, while the results are encouraging for these techniques at a minimum two-year follow-up, this time period is relatively short considering the expected lifespan of the prosthesis. Longer follow-up is necessary to evaluate implant survival, the ultimate fate of the graft, and whether the clinical outcomes seen in this study can be maintained.

Clinically important, acquired glenoid bone defects may not be uncommon and were present in 39% of the shoulders in this series of primary reverse shoulder arthroplasties. Osseous erosion may require alteration in operative technique such as the use of the spine centerline, bone-grafting, and larger glenospheres. Surgeons can anticipate and prepare for these altered techniques with preoperative identification of glenoid bone loss. The spine centerline allows for secure initial fixation of the glenoid baseplate in abnormal glenoids, regardless of the location or severity of bone loss. Larger glenosphere sizes can accommodate for bone loss and appropriately tension the soft-tissue envelope. These modifications may enable patients with acquired glenoid bone defects to obtain short-term functional outcomes similar to those of patients with normal morphology.

## Appendix

 Tables showing the preoperative subgroup comparisons, clinical outcomes, postoperative subgroup analysis, and anatomic measurements of the scapulae are available with the electronic version of this article on our web site at [jbjs.org](http://jbjs.org) (go to the article citation and click on "Supporting Data"). ■

NOTE: The authors acknowledge Jason Busse, DC, MSc, PhD, and Ola Alak, BA, for their efforts in the preparation of this manuscript.

Steven M. Klein, MD  
Page Dunning, BA  
Philip Mulieri, MD, PhD  
Derek Pupello, MBA

Mark A. Frankle, MD  
Florida Orthopaedic Institute (S.M.K., P.M., and M.A.F.)  
and Foundation for Orthopaedic Research and Education  
(P.D. and D.P.), 13020 North Telecom Parkway, Tampa, FL 33637.  
E-mail address for M.A. Frankle: frankle@pol.net

Katheryne Downes, MPH  
University of South Florida, 2 Tampa General Circle,  
STC 6029, Tampa, FL 33606

## References

- Werner CM, Steinmann PA, Gilbert M, Gerber C. Treatment of painful pseudo-paresis due to irreparable rotator cuff dysfunction with the Delta III reverse-ball-and-socket total shoulder prosthesis. *J Bone Joint Surg Am.* 2005;87:1476-86.
- Frankle M, Siegal S, Pupello D, Saleem A, Mighell M, Vasey M. The reverse shoulder prosthesis for glenohumeral arthritis associated with severe rotator cuff deficiency. A minimum two-year follow-up study of sixty patients. *J Bone Joint Surg Am.* 2005;87:1697-705.
- Cuff DJ, Virani NA, Levy J, Frankle MA, Derasari A, Hines B, Pupello DR, Cancio M, Mighell M. The treatment of deep shoulder infection and glenohumeral instability with debridement, reverse shoulder arthroplasty and postoperative antibiotics. *J Bone Joint Surg Br.* 2008;90:336-42.
- Levy J, Frankle M, Mighell M, Pupello D. The use of the reverse shoulder prosthesis for the treatment of failed hemiarthroplasty for proximal humeral fracture. *J Bone Joint Surg Am.* 2007;89:292-300.
- Norris TR, Kelly JD II, Humphrey CS. Management of glenoid bone defects in revision shoulder arthroplasty: a new application of the reverse total shoulder prosthesis. *Tech Shoulder Elbow Surg.* 2007;8:37-46.
- Wall B, Nové-Josserand L, O'Connor DP, Edwards TB, Walch G. Reverse total shoulder arthroplasty: a review of results according to etiology. *J Bone Joint Surg Am.* 2007;89:1476-85.
- Frankle M, Teramoto A, Luo ZP, Levy JC, Pupello D. Glenoid morphology in reverse shoulder arthroplasty: classification and surgical implications. *J Shoulder Elbow Surg.* 2009;18:874-85.
- Rice RS, Sperling JW, Milette J, Schleck C, Cofield RH. Augmented glenoid component for bone deficiency in shoulder arthroplasty. *Clin Orthop Relat Res.* 2008;466:579-83.
- Hill JM, Norris TR. Long-term results of total shoulder arthroplasty following bone-grafting of the glenoid. *J Bone Joint Surg Am.* 2001;83:877-83.
- Iannotti JP, Norris TR. Influence of preoperative factors on outcome of shoulder arthroplasty for glenohumeral osteoarthritis. *J Bone Joint Surg Am.* 2003;85:251-8.
- Cheung EV, Sperling JW, Cofield RH. Reimplantation of a glenoid component following component removal and allogenic bone-grafting. *J Bone Joint Surg Am.* 2007;89:1777-83.
- Cofield RH, Edgerton BC. Total shoulder arthroplasty: complications and revision surgery. *Instr Course Lect.* 1990;39:449-62.
- Seebauer L, Walter W, Keyl W. Reverse total shoulder arthroplasty for the treatment of defect arthropathy. *Oper Orthop Traumatol.* 2005;17:1-24.
- Visotsky JL, Basamania C, Seebauer L, Rockwood CA, Jensen KL. Cuff tear arthropathy: pathogenesis, classification, and algorithm for treatment. *J Bone Joint Surg Am.* 2004;86 Suppl. 2:35-40.
- Hamada K, Fukuda H, Mikasa M, Kobayashi Y. Roentgenographic findings in massive rotator cuff tears. A long-term observation. *Clin Orthop Relat Res.* 1990;254:92-6.
- Neyton L, Boileau P, Nové-Josserand L, Edwards TB, Walch G. Glenoid bone grafting with a reverse design prosthesis. *J Shoulder Elbow Surg.* 2007;16(3 Suppl):S71-8.
- Elhassan B, Ozbaydar M, Higgins LD, Warner JJ. Glenoid reconstruction in revision shoulder arthroplasty. *Clin Orthop Relat Res.* 2008;466:599-607.
- Levy JC, Virani N, Pupello D, Frankle M. Use of the reverse shoulder prosthesis for the treatment of failed hemiarthroplasty in patients with glenohumeral arthritis and rotator cuff deficiency. *J Bone Joint Surg Br.* 2007;89:189-95.
- Matsen FA III, Lippitt SB, DeBartolo SE, editors. *Shoulder surgery: principles and procedures.* Philadelphia: Saunders; 2004. p 569.
- Bicos J, Mazzocca A, Romeo AA. The glenoid center line. *Orthopedics.* 2005;28:581-5.
- Frankle M, Levy JC, Pupello D, Siegal S, Saleem A, Mighell M, Vasey M. The reverse shoulder prosthesis for glenohumeral arthritis associated with severe rotator cuff deficiency. A minimum two-year follow-up study of sixty patients. *Surgical technique. J Bone Joint Surg Am.* 2006;88 Suppl 1(Pt 2):178-90.
- Kocher MS, Horan MP, Briggs KK, Richardson TR, O'Holleran J, Hawkins RJ. Reliability, validity, and responsiveness of the American Shoulder and Elbow Surgeons subjective shoulder scale in patients with shoulder instability, rotator cuff disease, and glenohumeral arthritis. *J Bone Joint Surg Am.* 2005;87:2006-11.
- Godfrey J, Hamman R, Lowenstein S, Briggs K, Kocher M. Reliability, validity, and responsiveness of the simple shoulder test: psychometric properties by age and injury type. *J Shoulder Elbow Surg.* 2007;16:260-7.
- Cuff D, Pupello D, Virani N, Levy J, Frankle M. Reverse shoulder arthroplasty for the treatment of rotator cuff deficiency. *J Bone Joint Surg Am.* 2008;90:1244-51.
- Deloach J, Porucznik C, Green A, Powell A, Tashjian R. Determining the minimal clinically important difference (MCID) for the ASES score and the SST. Presented as a poster exhibit at the Annual Meeting of the American Academy of Orthopaedic Surgeons; 2009 Feb 25-27; Las Vegas, NV. Poster no. 321.
- Valenti PH, Boutens D, Nérot C. Delta 3 reversed prosthesis for osteoarthritis with massive rotator cuff tear: long term results. In: Walch G, Boileau P, Molé D, editors. *2000 shoulder prostheses. . . two to ten year follow-up.* Paris, France: Sau-ramps Medical; 2001. p 253-9.
- Neer CS 2nd, Craig EV, Fukuda H. Cuff-tear arthropathy. *J Bone Joint Surg Am.* 1983;65:1232-44.
- Cofield RH. Total shoulder arthroplasty with the Neer prosthesis. *J Bone Joint Surg Am.* 1984;66:899-906.
- Hawkins RJ, Greis PE, Bonutti PM. Treatment of symptomatic glenoid loosening following unconstrained shoulder arthroplasty. *Orthopedics.* 1999;22:229-34.
- Scalise JJ, Iannotti JP. Bone grafting severe glenoid defects in revision shoulder arthroplasty. *Clin Orthop Relat Res.* 2008;466:139-45.
- Neer CS 2nd, Morrison DS. Glenoid bone-grafting in total shoulder arthroplasty. *J Bone Joint Surg Am.* 1988;70:1154-62.
- Neyton L, Walch G, Nové-Josserand L, Edwards TB. Glenoid corticocancellous bone grafting after glenoid component removal in the treatment of glenoid loosening. *J Shoulder Elbow Surg.* 2006;15:173-9.
- Sirveaux F, Favard L, Oudet D, Huquet D, Walch G, Molé D. Grammont inverted total shoulder arthroplasty in the treatment of glenohumeral osteoarthritis with massive rupture of the cuff. Results of a multicentre study of 80 shoulders. *J Bone Joint Surg Br.* 2004;86:388-95.
- Parnes N, Rolf RH, Zimmer ZR, Higgins LD, Warner JJ. Management of failed hemiarthroplasty with reverse prosthesis. *Tech Shoulder Elbow Surg.* 2008;9:216-25.
- Neyton L, Sirveaux F, Roche O, Molé D, Boileau P, Walch G. [Results of revision surgery for glenoid loosening: a multicentric series of 37 shoulder prostheses]. *Rev Chir Orthop Reparatrice Appar Mot.* 2004;90:111-21. French.