



ELSEVIER

SHOULDER

## Radiographic comparison of pegged and keeled glenoid components using modern cementing techniques: A prospective randomized study

T. Bradley Edwards, MD<sup>a,\*</sup>, Joanne E. Labriola, MD<sup>a</sup>, Rodney J. Stanley, MD<sup>a</sup>, Daniel P. O'Connor, PhD<sup>b</sup>, Hussein A. Elkousy, MD<sup>a</sup>, Gary M. Gartsman, MD<sup>a</sup>

<sup>a</sup>Fondren Orthopedic Group, Texas Orthopedic Hospital, Houston, TX

<sup>b</sup>Laboratory of Integrated Physiology, University of Houston, Houston, TX

**Background:** Modern cementing techniques have improved glenoid fixation, reduced glenoid lucency seen with keeled components, and may eliminate differences attributable to glenoid design. The purpose of this study was to determine the effect of glenoid design on immediate and follow-up radiographic lucency of pegged and keeled glenoid components, using modern cementing techniques.

**Material and methods:** Fifty-three total shoulder arthroplasties were performed in patients with primary glenohumeral osteoarthritis. Patients were randomized prospectively to receive either a pegged or keeled glenoid component. Three raters graded radiographic glenoid lucencies.

**Results:** On immediate radiographs, there was no significant difference in the rate of glenoid lucency between pegged (0%) and keeled (15%) glenoid components ( $P = .128$ ). However, after an average of 26 months, the rate of glenoid lucency was significantly higher in patients with keeled components (46%) compared to patients with pegged components (15%) ( $P = .003$ ).

**Conclusion:** Even with modern cementing techniques, pegged glenoid components remain radiographically superior to keeled glenoid components.

**Level of evidence:** Level I, Randomized Clinical Trial, Treatment study.

© 2010 Journal of Shoulder and Elbow Surgery Board of Trustees.

**Keywords:** Shoulder; arthroplasty; reconstruction; adult; osteoarthritis; cement; component loosening

Glenoid loosening is the most common indication for revision total shoulder arthroplasty,<sup>9,11,12,16,25,31,32</sup> and loosening has been correlated with the development of glenoid radiographic lucency.<sup>2,3,5,14,20,27</sup> In a study by Torchia et al, early radiolucent lines were present in 93% of glenoid components that eventually developed radiographic

loosening, whereas similar lines were present in only 44% of glenoid components that did not develop radiographic loosening.<sup>27</sup>

Several biomechanical, animal, and retrospective studies have implicated glenoid design in the development of glenoid lucency, stating the superiority of pegged over keeled glenoid components.<sup>15,16,18,28,31</sup> In a prospective, randomized study with early cementing techniques, Gartsman et al also demonstrated the superiority of pegged glenoid components in the immediate postoperative period.<sup>8</sup> On postoperative radiographs, the rate of lucency

\*Reprint requests: T. Bradley Edwards, MD, 7401 S. Main St., Houston, TX 77030.

E-mail address: [bemd@fondren.com](mailto:bemd@fondren.com) (T.B. Edwards).

was significantly higher in patients with keeled components (39%) than the rate of lucency (5%) observed with pegged components,  $P = .026$ .<sup>8</sup>

Modern cementing techniques, however, have improved glenoid fixation and have reduced the rate and extent of glenoid lucency seen with keeled components.<sup>15,20,24,26</sup> Utilizing improved cementing techniques including burr curettage, lavage, glenoid drying, and cement pressurization, Norris and Lachiewicz found a lower frequency of radiolucent lines on immediate postoperative radiographs than previously reported with older techniques.<sup>24</sup> After an average follow-up period of 5 years, a decrease in early radiolucent lines was associated with improved survivorship (97% at 5 years, 93% at 8 years) and a low rate of component loosening (6%).<sup>24</sup> Szabo et al demonstrated improved radiolucent line scores using glenoid preparation and cementing with compaction of the cancellous bone of the glenoid compared to burr curettage.<sup>26</sup> On immediate postoperative radiographs, glenoids prepared with the compaction technique had a lower rate of glenoid lucencies around the keel (11%) than the glenoids prepared with the curettage technique (38%).<sup>26</sup> Furthermore, the glenoids prepared with the compaction technique showed a decreased rate of progression of the radiolucent lines after 2 years of follow-up.<sup>26</sup> With these modern cementing techniques, the difference in glenoid lucency between pegged and keeled glenoid components may be minimized or eliminated.

The purpose of this study was to determine the effect of glenoid design on the immediate and mid-term follow-up radiographic lucency of pegged and keeled glenoid components using modern cementing techniques. With improved glenoid preparation and cementing techniques, our hypothesis was that there would be minimal or no difference in radiographic lucency between pegged and keeled glenoid components on immediate and follow-up radiographs.

## Materials and methods

### Subjects

The study was approved by our institutional review board. Patients were recruited to participate by their surgeon and indicated their willingness to participate by signing informed consent. This study was a prospective, randomized trial. The patients were not told which glenoid component design they had received. Patients undergoing total shoulder arthroplasty were included in this study if they had a diagnosis of primary glenohumeral osteoarthritis and a glenoid that did not require bone grafting. In addition, all patients in this study had a complete preoperative radiographic assessment, including an anteroposterior radiograph and computed tomographic arthrography, for evaluation of the rotator cuff and morphologic features of the glenoid. Glenoid morphology was classified according to the classification of Walch et al.<sup>29</sup>

To maintain a pure series of patients with primary osteoarthritis, patients with an inflammatory arthropathy in their shoulder (rheumatoid arthritis, systemic lupus erythematosus, ankylosing spondylitis), osteochondromatosis, acromegaly, Paget's disease,

postinfectious arthropathy, skeletal dysplasia, neurologic problems (Charcot arthropathy, Parkinson's disease), and osteonecrosis were excluded. Patients with a history of shoulder trauma (fracture or soft tissue injury), instability (surgically or nonsurgically treated), or prior shoulder surgery also were excluded. Finally, patients with marked rotator cuff disorders of their shoulder, as indicated by acromiohumeral arthritis, a massive rotator cuff tear, or a rotator cuff tear involving the infraspinatus or subscapularis, also were excluded because the etiology of their shoulder disease might not have been primary glenohumeral osteoarthritis.

A power analysis conducted prior to the study ( $5 \times 2$  Chi-square test, 1-tailed  $\alpha = 0.05$ ,  $\beta \leq 0.20$ ),  $\Delta^2 = 0.14$ ,  $\pi_0 = 0.20$ ,  $V[\pi_0] = 0.02$ ) determined that at least 18 patients per group would be required to identify an average difference of 1 lucency grade (see below) between the pegged and keeled glenoid components to obtain a power of greater than 80%. Fifty patients (53 shoulders) with average age of  $69 \pm 11$  years were enrolled in this study. The additional shoulders (beyond 18 in each group) were enrolled to ensure the study would have sufficient power should patients be lost to follow-up. Twenty-six shoulders were randomized to receive a pegged glenoid component and 27 shoulders were randomized to receive a keeled glenoid component; all patients received the component to which they were randomized. A simple randomization technique using a random numbers table (odd = pegged, even = keeled) with glenoid component type placed in sealed envelopes was employed. The design of the glenoid component, pegged versus keeled, was determined by opening a randomly selected envelope immediately preoperatively without any specific indication.

### Surgical procedure

Fifty-three total shoulder arthroplasties were performed on patients with primary glenohumeral osteoarthritis who agreed to participate in this study over a 1-year period from December of 2004 to December of 2005. All patients in this series underwent primary total shoulder arthroplasty by a single surgeon using the Aequalis prosthesis (Tornier, Mont Bonnot, France). A standard deltopectoral approach was employed in all cases. A subscapularis tenotomy was performed at the anatomic neck of the humerus. The subscapularis tendon was mobilized by releasing the glenohumeral ligaments and glenohumeral capsule. Next, the humeral head was dislocated and peripheral osteophytes were removed. The humeral head cut was made along the anatomic neck of the humerus. The humerus was prepared to accept a press fit prosthesis. Six different size prosthetic humeral head diameters, varying between 39 and 50 mm, were used.

Attention was then turned toward implantation of the glenoid component. Following creation of a centering hole, the glenoid face was prepared with a concentric reamer chosen in relation to the glenoid component size. Four different size glenoid components were used with radii of curvature of 23.5, 26.5, 28, and 30.5 mm. The goal of reaming was to remove any residual articular cartilage, correct deformity detected on the preoperative computed tomographic arthrography, and create a congruent base for the convex back glenoid component. Glenoid biconcavity was corrected to physiologic version as judged by when the surgeon had corrected the biconcavity through reaming.

In 27 shoulders, a keeled glenoid component was used. The convex-back, polyethylene, pear-shaped glenoid component used

in this study was equipped with a keel that is 4 mm thick and 15 mm in length and designed for cementation into the medullary canal of the glenoid. The dimensions of the keel are the same for all glenoid component sizes. During glenoid preparation, the keel slot was created using a drill and instrumented guides to assure proper size and position of the slot. The glenoid keel slot was prepared using the “compaction” technique developed by Gaz-ielly and described by Boileau et al.<sup>3</sup> Rather than removing cancellous bone, the glenoid component was implanted after the cancellous bone was compacted with a glenoid punch of the same dimensions as the keel. In 26 shoulders, a pegged glenoid component with 1 central peg and 3 peripheral pegs was used. A peripheral hole drill guide was inserted into the previously made centering hole and the 3 peripheral holes were drilled to the same dimensions as the pegs. The pegged component has small flutes cut into the pegs to allow for interdigitation of the cement. Furthermore, the back of the component is textured to allow further interdigitation, as the cement extrudes out of the drilled holes and contacts the back of the component during component impaction. The interdigitation of cement in the cancellous bone and in the texturing of the pegs and back of the component hold the component in place.

Cementing was performed with modern pressurization techniques.<sup>24</sup> The prepared glenoid was cleansed of blood and bone fragments with saline solution lavage followed by sponge drying.<sup>6</sup> Cement was introduced under pressure using a catheter tip syringe. No cement was placed between the back of the glenoid component and the glenoid bone. The glenoid component was then impacted, further pressurizing the cement into the cancellous bone, and manually held until the cement polymerized. The final humeral component was placed, the subscapularis was closed using transosseous and transtendinous sutures, and the wound was closed in layers.

Postoperatively, the patients were placed in a standard sling. After 1 week, aquatic therapy rehabilitation was initiated to begin shoulder range of motion in elevation, extension, horizontal adduction, internal rotation, and external rotation.<sup>19</sup> External rotation was limited to neutral for 4 weeks. After at least 5 weeks of hydrotherapy, if acceptable range of motion was gained, patients graduated to a self-directed land based program. Strengthening exercises were not prescribed.

## Radiographic lucency

Radiographs were obtained within 7 days of the surgical procedure and then yearly during the follow-up period. All radiographs in this series were obtained using a standardized fluoroscopic and magnification controlled technique to ensure that the x-ray beam was perpendicular to the plane of the bone-implant interface, as determined by the use of a wire embedded in the polyethylene.<sup>13</sup> Radiographic lucency of the keeled glenoid components was graded according to criteria previously described by Franklin et al,<sup>7</sup> and the pegged components were graded according to the modification described by Lazarus et al.<sup>18</sup> The keeled and pegged components were graded between 0 and 5. A grade of 0 or 1 was considered negligible glenoid lucency (Tables I and II).

The radiographs were analyzed with a digital radiographic viewer (SwissVision Workstation; SwissRay, East Brunswick, NJ), which allowed manipulation of the image for optimal evaluation, thus obviating imprecisions related to image magnification as may occur with plain film radiographs.<sup>10</sup> The uncompressed DICOM images were viewed on high-resolution monitors at a single viewing

**Table I** Grading system for keeled glenoid components

1	Radiolucency at inferior and/or superior flange
2	Incomplete radiolucency at keel
3	Complete radiolucency ( $\leq 2$ mm wide) around keel
4	Complete radiolucency ( $\geq 2$ mm wide) around keel
5	Gross loosening

station in the clinic under standard fluorescent ambient lighting and free from glare. Any radiolucencies were measured with the digital caliper within the radiographic viewer. The radiographs were evaluated by 3 raters who independently graded the radiographs for each of the patients in this study. All immediate postoperative radiographs were evaluated by each rater at a single sitting within a single day; the follow-up radiographs were also evaluated by each rater at a single sitting on a different day to avoid “side-by-side” comparisons of a patient’s 2 radiographs. The final lucency grade used in data analysis was the grade assigned independently by at least 2 of the 3 raters (ie, a single discordant grade was ignored). In no case did all 3 raters disagree on the lucency grade.

## Statistical analysis

The Chi-squared test was used to evaluate the effect of glenoid component design on immediate and follow-up radiographs. Chi-squared tests were also used to evaluate whether glenoid component groups differed with respect to age, gender, shoulder dominance, humeral head size, glenoid component size, mismatch of radius of curvature between the glenoid and humeral components, or glenoid morphology. Chi-squared tests were also used to evaluate whether age, gender, shoulder dominance, glenoid morphology, humeral head size, glenoid component size, or glenohumeral mismatch were related to immediate and follow-up postoperative radiolucency of the glenoid component. Statistical significance was set at  $P = .05$ . Interobserver reliability was evaluated using intraclass correlation coefficients of Shrout and Fleiss type, which estimates the consistency of the composite lucency scores for these 3 raters.

## Results

Table III lists the demographic data for the patients returning for follow-up who received pegged and keeled glenoid components. Patient gender ( $P = .381$ ), age ( $P = .098$ ), shoulder dominance ( $P = .244$ ), glenoid morphology ( $P = .066$ ), humeral head size ( $P = .221$ ), glenoid component size ( $P = .121$ ), glenohumeral mismatch ( $P = .055$ ), and length of follow-up ( $P = .933$ ) did not differ significantly between patients who received pegged glenoid components and patients who received keeled glenoid components.

**Table II** Grading system for pegged glenoid components

1 Incomplete radiolucency around 1 or 2 pegs
2 Complete radiolucency ( $\leq 2$ mm wide) around 1 peg only, with or without incomplete radiolucency around 1 other peg
3 Complete radiolucency ( $\leq 2$ mm wide) around 2 or more pegs
4 Complete radiolucency ( $\geq 2$ mm wide) around 2 or more pegs
5 Gross loosening

**Immediate radiographic lucency**

Fifty-one patients (96%) returned for immediate post-operative radiographs, including 26 patients in the keel group (96%) and 25 patients in the pegged group (96%). Figure 1 shows the lucency grades for the pegged and keeled glenoid components. In the immediate postoperative period, there was no significant difference in the rate of glenoid lucency (of at least grade 2) between the pegged (0%) and keeled (15%) glenoid components,  $P = .128$ .

Furthermore, patient gender ( $P = .168$ ), age ( $P = .133$ ), shoulder dominance ( $P = .361$ ), glenoid morphology ( $P = .395$ ), humeral head size ( $P = .291$ ), glenoid component size ( $P = .234$ ), and glenohumeral mismatch ( $P = .493$ ) were not significantly related to the glenoid component lucencies.

**Follow-up radiographic lucency**

Forty-seven patients (89%) returned for follow-up evaluation (average 26 months; range, 12-38), including 26 patients in the keel group (96%) and 21 patients in the pegged group (81%). Two patients in the keel group had failure of their component (see below) and are not included in the radiolucent line evaluation, leaving 24 patients in the keel group. Of the 5 patients in the pegged group who did not return for the follow-up evaluation, 2 were deceased (implant was in place and had not been revised at time of death), 2 had returned to practice as surgeons and reported no substantial problems, and 1 could not be located. Figure 2 shows the lucency grades for the pegged and keeled glenoid components. After an average follow-up of 26 months, the rate of glenoid lucency (of at least grade 2) was significantly higher in patients with a keeled glenoid component (46%) compared to patients with a pegged glenoid component (15%),  $P = .003$ .

Glenoid lucency progressed (at least 1 grade) between postoperative radiographs and follow-up radiographs in 29% of patients, including 10 patients with keeled glenoid components (42%) and 3 patients with pegged glenoid

**Table III** Demographic data for patients with pegged and keeled glenoid components

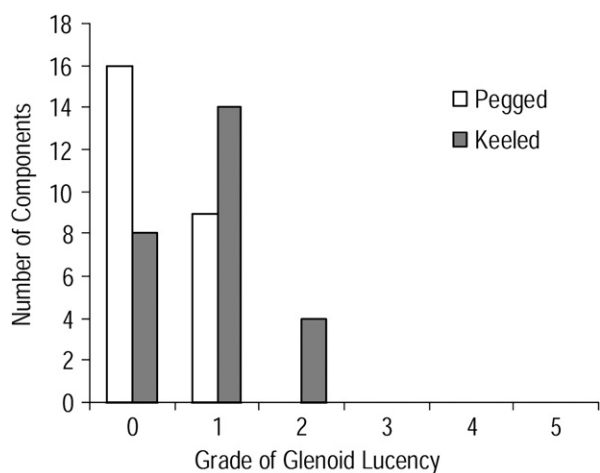
	Pegged	Keeled	
Number	21	26	
Average age (years)	71.8 $\pm$ 10.4	66.3 $\pm$ 11.6	$P = .098$
Dominant side	13	11	$P = .244$
Gender:			$P = .381$
Male	13	12	
Female	8	14	
Glenoid morphology <sup>27</sup> :			$P = .066$
A1	9	16	
A2	5	0	
B1	1	2	
B2	6	7	
C	0	1	
Humeral head size:			$P = .221$
39	1	3	
41	3	2	
43	2	9	
46	6	7	
48	5	4	
50	4	1	
Glenoid size:			$P = .121$
S	1	3	
M	5	9	
L	9	13	
XL	6	1	
Mismatch	7.9 $\pm$ 1.8	7.0 $\pm$ 1.1	$P = .055$

components (14%). The rate of progression and the final grade of glenoid lucency were higher in patients with keeled glenoid components compared to patients with pegged glenoid components ( $P = .044$ ; Figure 3).

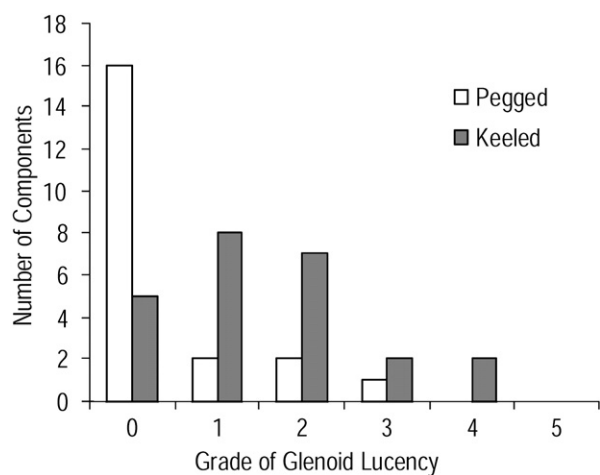
Glenoid lucency was not significantly related to patient age ( $P = .174$ ), shoulder dominance ( $P = .615$ ), glenoid morphology ( $P = .333$ ), or glenohumeral mismatch ( $P = .923$ ). Glenoid lucency was related to gender on follow-up radiographs ( $P = .011$ ). Females had a significantly (38%) higher rate of glenoid lucency than males in patients with pegged glenoid components (38% vs 0%,  $P = .049$ ). Females also had a 27% higher rate of glenoid lucency than males in patients with keeled glenoid components; but, with the numbers available, this difference did not reach statistical significance (57% vs 30%,  $P = .240$ ). Increasing glenoid lucency was also related to smaller head size ( $P = .004$ ) and smaller glenoid size ( $P = .002$ ); however, females received a smaller head size ( $P < .001$ ) and glenoid size ( $P < .001$ ) than males, and component size was not related independently to the rate of glenoid lucency after accounting for this gender disparity in component size.

**Failures**

Over the follow-up period, total shoulder arthroplasties in 2 patients with keeled glenoid components failed, whereas there were no failures in patients with pegged glenoid



**Figure 1** Grades of glenoid lucency for pegged and keeled glenoid components on postoperative radiographs. In the immediate postoperative period, there was no significant difference in the rate of glenoid lucency (of at least grade 2) between the pegged (0%) and keeled (15%) glenoid components,  $P = .128$ .



**Figure 2** Grades of glenoid lucency for pegged and keeled glenoid components on follow-up radiographs. After an average follow-up of 26 months, the rate of glenoid lucency (of at least grade 2) was significantly higher in patients with a keeled glenoid component (46%) compared to patients with a pegged glenoid component (15%),  $P = .003$ .

components. One patient failed secondary to a posterior dislocation and was revised to a reverse total shoulder arthroplasty. The second patient failed secondary to fracture of the glenoid component following a fall. This patient was treated with removal of the fractured glenoid component and bone grafting of the glenoid.

### Inter-rater reliability and agreement

On the immediate postoperative radiographs, the lucency grades had good reliability (0.70) and all 3 raters were in

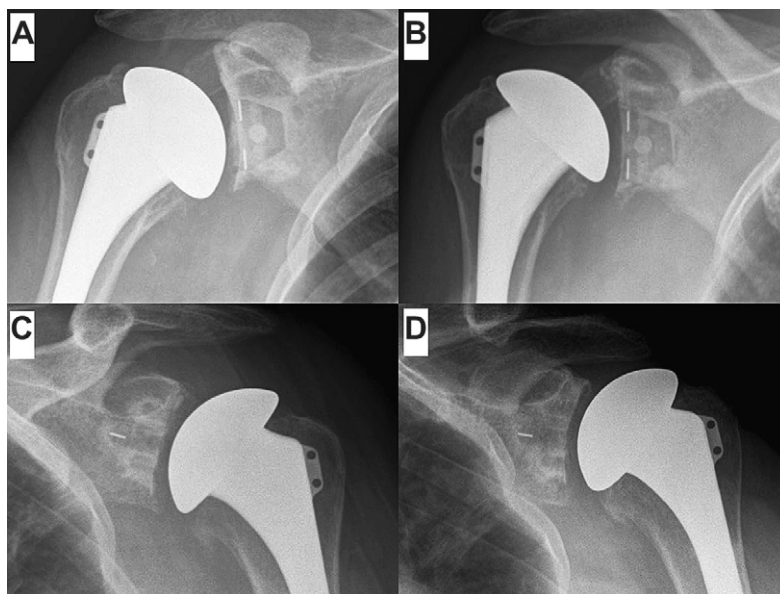
complete agreement for 80% of the lucency grades. On the follow-up radiographs, the lucency grades had good reliability (0.85) and all 3 raters were in complete agreement for 82% of the lucency grades.

### Discussion

This study evaluated the effect of glenoid design on the immediate and mid-term radiographic lucency of pegged and keeled glenoid components using modern cementing techniques. Although there were no significant differences in rates of glenoid lucency in the immediate postoperative period, pegged glenoid components had significantly less glenoid lucency than keeled glenoid components after an average follow-up of 26 months. We had hypothesized that with improved glenoid preparation and cementing techniques, there would be no difference in radiographic lucency between pegged and keeled glenoid components on postoperative and follow-up radiographs. Our results partially support our hypothesis. The use of modern cementing techniques, including glenoid compaction and cement pressurization, was able to minimize differences in glenoid lucency seen between pegged and keeled glenoid components in the immediate postoperative period. However, these results were not sustained. As follow-up increased, patients with keeled glenoid components had a significantly higher rate of glenoid lucency than patients with pegged glenoid components. Even with modern cementing techniques, pegged glenoid components were radiographically superior to keeled glenoid components.

Using a similar study design and radiographic lucency grading system, Gartsman et al found glenoid lucencies in 39% of patients with keeled glenoid components and 5% of patients with pegged glenoid components on postoperative radiographs.<sup>8</sup> The current study demonstrated a lower rate of postoperative glenoid lucency in both keeled (15%) and pegged (0%) glenoid components. The lower rates of glenoid lucency seen in this study may be attributable to modern cementing techniques, including glenoid compaction and cement pressurization. The rate of glenoid lucency seen with the keeled components in this study is similar to the rates seen in other studies that have used modern cementing techniques. For example, Mileti et al showed immediate glenoid lucency in 14% of keeled glenoid components and Szabo et al showed immediate glenoid lucency in 11% of keeled components, which increased to 17% after 2 years of follow-up.<sup>20,26</sup>

Radiographic lucencies seen with both pegged and keeled components increased as follow-up increased; however, the rate of progression and the final grade of glenoid lucency were greater in patients with keeled glenoid components. Length of follow-up was similar between the 2 glenoid groups. Patient age, glenoid morphology, and glenohumeral mismatch were unrelated to glenoid lucency and thus could not have contributed to the higher rate of



**Figure 3** A, Postoperative radiograph of a keeled glenoid component (grade 0 lucency). B, Twelve-month follow-up radiograph of the same keeled component demonstrating grade 3 lucency. C, Postoperative radiograph of a pegged glenoid component (grade 0 lucency). D, Three-year follow-up radiograph of the same pegged component demonstrating grade 0 lucency.

lucency in the keeled components. Glenoid mismatch in particular has been shown in prior work to be related to the prevalence of radiolucent lines, which increase risk of component loosening.<sup>23,30</sup> In particular, radiolucencies are worse when mismatch is less than 6 cm<sup>30</sup>; all subjects in the current study had glenoid mismatch of 6 cm or greater, which may explain the lack of its effect on glenoid lucency. Furthermore, the length of follow-up in these previous studies was considerably longer than in the current study. It is possible that mismatch may lead to greater lucency or component failure, as time from surgery increases in our patients.

Previous studies have also documented progression of radiolucent lines with increased follow-up, with rates varying from 6% to 76%.<sup>4,5,20,22,24</sup> As previously stated by Neer, progression of radiolucent lines is the most concerning finding and may be used to identify glenoid components that are at risk for loosening.<sup>21</sup> Therefore, patients receiving keeled glenoid components in this study may be more at risk for glenoid loosening than patients receiving pegged glenoid components. The scope of this paper did not include investigation of mechanical, biological, or histological mechanisms that are potentially related to presence of radiolucent lines. Our results show some clinical manifestations of the previous biomechanical research demonstrating the ability of pegged glenoid components to better resist displacement forces, as compared to keeled components.<sup>1,29</sup>

As follow-up increased, 2 patient variables became significantly related to glenoid lucency. First, female patients were shown to have higher rates of glenoid lucency than male patients. This gender difference had not been

seen in previous studies and may be related to increased rates of osteoporosis in female patients compared to male patients. In addition, smaller humeral head size and smaller glenoid size were associated with higher rates of glenoid lucency. This affect appears to be secondary to the fact that females received smaller component sizes. Future studies are needed to define the association between gender and glenoid lucency; and to develop treatment strategies to decrease the rate of glenoid lucency seen in female patients.

One advantage of this study was its design. Our inclusion and exclusion criteria were formulated to allow us to study a relatively pure series of patients with primary glenohumeral osteoarthritis. With a prospective, randomized study design, we were able to create 2 groups of patients that did not significantly differ from one another except in glenoid component design, to control for variables that are known to affect glenoid lucency, and to minimize the effect of unknown confounding variables. In addition, we eliminated selection bias of the operating surgeon.

One limitation of this study is in its radiographic evaluation and the limited scoring systems available for grading periglenoid radiolucencies. Although we followed protocols and grading systems that had been used by other authors, there is no clear correlation between the radiographic score assigned to a pegged component and the same score given to a keeled component.<sup>8,18</sup> In fact, the scoring systems may be biased in favor of the pegged components. For example, an incomplete radiolucency around the keel of a glenoid component receives a grade of 2, whereas a similar incomplete radiolucency around a peg only receives a grade of 1. Future studies may help to refine the grading criteria for

better comparison between pegged and keeled glenoid components. Another limitation of this study is that the raters could not be blinded to glenoid component design. Our study, however, did demonstrate a high level of interobserver consistency in radiographic evaluation.

## Conclusion

This study supports the results of previous biomechanical, animal, retrospective, and prospective studies.<sup>8,15-18,28,31</sup> Even with modern cementing techniques, pegged glenoid components remain radiographically superior to keeled glenoid components. In patients with primary glenohumeral osteoarthritis, the use of pegged glenoid components for total shoulder arthroplasty decreases the rate of glenoid lucency. Additional studies are needed to investigate the long-term radiographic and clinical significance of these findings.

## Disclaimer

Two authors (TBE and GMG) acknowledge that they are consultants for Tornier and have received research and educational support from Tornier. None of the other authors have received financial remuneration related to or in support of this work. This study was approved by the Texas Orthopedic Hospital Institutional Review Board, as protocol #TOH040.

## References

1. Anglin C, Wyss UP, Nyffeler RW, Gerber C. Loosening performance of cemented glenoid prosthesis design pairs. *Clin Biomech* 2001;16:144-50.
2. Barrett WP, Franklin JL, Jackins SE, Wyss CR, Matsen FA III. Total shoulder arthroplasty. *J Bone Joint Surg Am* 1987;69A:865-72.
3. Boileau P, Avidor C, Krishnan SG, Walch G, Kempf J, Mole D. Cemented polyethylene versus uncemented metal-backed glenoid components in total shoulder arthroplasty: A prospective, double-blind, randomized study. *J Shoulder Elbow Surg* 2002;11:351-9.
4. Boileau P, Molé D, Walch G. Technique of glenoid resurfacing in shoulder arthroplasty. In: Walch G, Boileau P, editors. *Shoulder arthroplasty*. Berlin: Springer-Verlag; 1999. p. 147-62.
5. Cofield RH. Total shoulder arthroplasty with the Neer prosthesis. *J Bone Joint Surg Am* 1984;66A:899-906.
6. Edwards TB, Sabonghy EP, Elkousy H, Warnock KM, Hammerman SM, O'Connor DP, et al. Glenoid component insertion in total shoulder arthroplasty: Comparison of three techniques for drying the glenoid before cementation. *J Shoulder Elbow Surg* 2007;16:107S-10.
7. Franklin JL, Barrett WP, Jackins SE, Matsen FA III. Glenoid loosening in total shoulder arthroplasty. Association with rotator cuff deficiency. *J Arthroplasty* 1988;3:39-46.
8. Gartsman GM, Elkousy HA, Warnock KM, Edwards TB, O'Connor DP. Radiographic comparison of pegged and keeled glenoid components. *J Shoulder Elbow Surg* 2005;14:252-7.
9. Hasan SS, Leith JM, Campbell B, Kapil R, Smith KL, Matsen FA III. Characteristics of unsatisfactory shoulder arthroplasties. *J Shoulder Elbow Surg* 2002;11:431-41.
10. Havig MT, Kumar A, Carpenter W, Seiler JG. Assessment of radiolucent lines about the glenoid: an in vitro radiographic study. *J Bone Joint Surg Am* 1997;79A:428-32.
11. Hawkins RJ, Bell RH, Jallay B. Total shoulder arthroplasty. *Clin Orthop Relat Res* 1989;242:188-94.
12. Ibarra C, Dines DM, McLaughlin JA. Glenoid replacement in total shoulder arthroplasty. *Orthop Clin North Am* 1998;29:403-13.
13. Kelleher IM, Cofield RH, Becker DA, Beabout JW. Fluoroscopically positioned radiographs of total shoulder arthroplasty. *J Shoulder Elbow Surg* 1992;1:306-11.
14. Kelly IG, Foster RS, Fisher WD. Neer total shoulder replacement in rheumatoid arthritis. *J Bone Joint Surg Br* 1987;69B:723-6.
15. Klepps S, Chiang AS, Miller S, Jiang CY, Hazrati Y, Flatow EL. Incidence of early radiolucent glenoid lines in patients having total shoulder replacements. *Clin Orthop Relat Res* 2005;435:118-25.
16. Lacroix D, Murphy LA, Prendergast PJ. Three-dimensional finite element analysis of glenoid replacement prostheses: a comparison of keeled and pegged anchorage systems. *J Biomech Eng* 2000;122:430-6.
17. Lacroix D, Prendergast PJ. Stress analysis of glenoid component designs for shoulder arthroplasty. *Proc Inst Mech Eng [H]* 1997;211:467-74.
18. Lazarus MD, Jensen KL, Southworth C, Matsen FA III. The radiographic evaluation of keeled and pegged glenoid component insertion. *J Bone Joint Surg Am* 2002;84A:1174-82.
19. Liotard JP, Edwards TB, Padey A, Walch G, Boulahia A. Hydrotherapy rehabilitation after shoulder surgery. *Tech Shoulder Elbow Surg* 2003;4:44-9.
20. Mileti J, Boardman ND III, Sperling JW, Cofield RH, Torchia ME, O'Driscoll SW, et al. Radiographic analysis of polyethylene glenoid components using modern cementing techniques. *J Shoulder Elbow Surg* 2004;13:492-8.
21. Neer C. Glenohumeral arthroplasty. In: Neer C, editor. *Shoulder reconstruction*. Philadelphia: WB Saunders; 1990. p. 143-269.
22. Neer C, Watson K, Stanton J. Recent experience in total shoulder replacement. *J Bone Joint Surg Am* 1982;64A:319-37.
23. Nho SJ, Ala OL, Dodson CC, Figgie MP, Wright TM, Craig EV, et al. Comparison of conforming and nonconforming retrieved glenoid components. *J Shoulder Elbow Surg* 2008;17:914-20.
24. Norris BL, Lachiewicz PF. Modern cement technique and the survivorship of total shoulder arthroplasty. *Clin Orthop Relat Res* 1996;328:76-85.
25. Skirving AP. Total shoulder arthroplasty — current problems and possible solutions. *J Orthop Sci* 1999;4:42-53.
26. Szabo I, Buscayret F, Edwards TB, Nemoz C, O'Connor DP, Boileau P, et al. Radiographic comparison of two glenoid preparation techniques in total shoulder arthroplasty. *Clin Orthop Relat Res* 2005;431:104-10.
27. Torchia ME, Cofield RH, Settergren CR. Total shoulder arthroplasty with the Neer prosthesis: long-term results. *J Shoulder Elbow Surg* 1997;6:495-505.
28. Trail IA, Nuttall D. The results of shoulder arthroplasty in patients with rheumatoid arthritis. *J Bone Joint Surg Br* 2002;84B:1121-5.
29. Walch G, Badet R, Boulahia A, Khoury A. Morphologic study of the glenoid in primary glenohumeral osteoarthritis. *J Arthroplasty* 1999;14:756-60.
30. Walch G, Edwards TB, Boulahia A, Boileau P, Mole D, Adeleine P. The influence of glenohumeral prosthetic mismatch on glenoid radiolucent lines: results of a multicenter study. *J Bone Joint Surg Am* 2002;84:2186-91.
31. Wirth MA, Korvick DL, Basamania CJ, Toro F, Aufdemorte TB, Rockwood CA Jr. Radiologic, mechanical, and histologic evaluation of 2 glenoid prosthesis designs in a canine model. *J Shoulder Elbow Surg* 2001;10:140-8.
32. Wirth MA, Rockwood CA Jr. Complications of total shoulder replacement arthroplasty. *J Bone Joint Surg Am* 1996;78A:603-16.